Attenuation of Acetic Acid-Induced Ulcerative Colitis in Rats by *Uvaria chamae* P. Beauv. (Annonaceae) Stem-Bark Extract

Thomas Abu[1,3*], Oyindamola O. Abiodun[2], Omonike O. Ogbole[3] and Edith O. Ajaiyeoba[3]

[1]Bioresources Development Centre, Odi, National Biotechnology Development Agency, Abuja, Nigeria
[2]Department of Pharmacology and Therapeutics, Faculty of Basic Medical Sciences, College of Medicine, University of Ibadan, Ibadan, Nigeria
[3]Department of Pharmacognosy, Faculty of Pharmacy, University of Ibadan, Ibadan, Nigeria

Corresponding Author: thomdgreat017@gmail.com

Abstract
The current drugs available for treating ulcerative colitis (UC) have proven to be effective but they also pose a risk of significant side effects and may interact with other medications. Hence, it is crucial to explore alternative treatments that provide both efficacy and reduced toxicity. This study aimed to evaluate the anti-inflammatory and oxidative stress inhibitory effects of *Uvaria chamae* stem-bark extract on acetic acid-induced acute colitis in rats, as identified in previous ethnobotanical research. The rats were given a 4% acetic acid solution by administering it into their colon through a rubber cannula at a dose of 4 mL/kg. *U. chamae* (50-400 mg/kg) and the standard drug, prednisolone (2 mg/kg), were orally administered 48 h, 24 h and 1 h before colitis induction, and continued for one week. The animals were assessed daily, and changes in body weight, water intake, and stool consistency were scored. Various markers of colonic inflammation, such as myeloperoxidase (MPO) activity, superoxide dismutase (SOD) level, and reduced glutathione content (GSH), were analyzed. In addition, the crude and partitioned fractions were tested for their potential to inhibit nitric oxide (NO). Results: In the untreated group, the rats showed increased colonic wall thickness, edema, diffuse inflammatory cell infiltration, decreased GSH, decreased SOD, and increased MPO activities. In contrast, the extract doses (50-400 mg/kg) showed a significant ($P<0.05$) reduction in macroscopic inflammation scores, mitigated morphological alterations, and increased mucus secretion. There was no significant difference among the treatment groups, indicating that *U. chamae* extract may be effective at all dose levels. The butanol fraction (1.31±0.09 µg/mL) exhibited the highest inhibitory potential against nitric oxide (NO) compared to the standard, gallic acid (1.1±0.1 µg/mL). These findings suggest that *U. chamae* could be a promising treatment option for Inflammatory Bowel Diseases (IBD).

Keywords: Anti-inflammatory, oxidative stress, prednisolone, ulcerative colitis, nitric oxide

Introduction

Inflammatory bowel disease (IBD) is a chronic inflammation that occurs in the gastrointestinal (GI) tract, resulting in conditions such as ulcerative colitis (UC) or Crohn's disease (CD) due to immune system activation. The prevalence of these disorders varies globally, reflecting their heterogeneity in IBD epidemiology (Sood *et al.*, 2003). Regions like Northern Europe, Western Europe, and North America have a high prevalence of ulcerative colitis (UC), mainly peaking between the ages of 20 and 25. However, UC is becoming increasingly prevalent in underdeveloped and developing countries like Nigeria, and it is recognized as a growing global health concern (Akinyinka *et al.*, 2019; Kuenzig *et al.*, 2022). The pathogenesis of UC has been associated with various factors, including genetic, immunological, and environmental factors (Kobayashi *et al.*, 2020). Despite numerous intensive research studies, the precise pathophysiology of the disease remains elusive (Keshteli *et al.*, 2019).

Ulcerative colitis primarily affects the inner lining (mucosa) of the colon (large intestine), typically affecting the rectum but occasionally extending to the entire colon (Taylor and Lobo, 2016). Common symptoms include diarrhea, abdominal cramps, and rectal bleeding, characterized by strong inflammatory reactions, widespread superficial mucosal ulceration, and leukocyte migration to the mucosal membrane (Reiff and Kelly, 2010). This inflammatory process generates mediators, including cytokines, arachidonic acid metabolites, and free radicals, leading to concurrent oxidative damage to the colonic mucosa (Pavlick *et al.*, 2002).

Managing UC effectively with treatments that minimize harm is a significant challenge. Commonly prescribed drugs for UC include 5-aminosalicylic acid, corticosteroids, azathioprine, 6-mercaptopurine, methotrexate, cyclosporine, antibiotics (such as metronidazole, ciprofloxacin, and vancomycin), and the TNF antagonist, infliximab (Fukuda *et al.*, 2019). However, the long-term usage of these drugs is limited by their lack of specificity, severe negative side effects, inconvenience associated with dose schedules, and high cost (Lin *et al.*, 2019).

Therefore, there is an urgent need to develop a new therapeutic approach that combines effectiveness with convenient dosing and offers more affordable and fewer side effects to enhance the quality of life and psychosocial functioning of patients. Various medicinal plants are known for their anti-inflammatory and antioxidant properties. We focused on *U. chamae*, also known as a bush banana, which has historical use as a folk remedy for treating wounds, sores, injuries, and swellings (Ayensu, 1978). Extracts from *U. chamae* leaves, roots, and stem bark have demonstrated antimicrobial, anti-inflammatory, hepatoprotective, antidiabetic, and antimalarial properties(Okwu and Iroabuchi, 2009; Abu *et al.*, 2018).

The biochemical and toxicological effects of leaf, root, and stem extracts of *U. chamae* in experimental animals have also been documented (Yakubu and Fayemo, 2021). Phytochemicals such as terpenes, cardiac glycosides, flavonoids, and saponins have been identified, contributing to the establishment of a protective mucus barrier that aids in ulcer healing (Coelho *et al.*, 2020). In this current study, we evaluated the anti-inflammatory effect of *U. chamae* stem bark methanol crude extract on the intestine. This evaluation involved measuring tumor necrosis factor-alpha (TNF-α), various biochemical markers, as well as macroscopic and histopathologic (microscopic) parameters associated with tissue damage in an experimental model of ulcerative colitis induced by Acetic Acid in Wistar rats. Additionally, we determined the nitric oxide inhibitory activity of both the crude extract and its partitioned fractions.

Materials and Methods

Plant material

The stem bark of *U. chamae* was collected from Oke-Ado at United Missionary College (U.M.C) premises. The plant was identified and authenticated by Mr Shasanya Olufemi at Forest Herbarium Ibadan (FHI), Jericho Ibadan. The voucher specimen (FHI number: 109900) was prepared and deposited in the Department of Pharmacognosy Herbarium and Forest Herbarium Ibadan. The plant material collected was dried under shade and ground into powder.

Plant Extraction

A quantity of 2 kg of powdered material underwent cold maceration using redistilled methanol for 72 h. The extract was subsequently filtered and the solvent was evaporated *in vacuo* using a rotary evaporator at about 40°C. The resulting yield was determined and plant extract was stored in the refrigerator at 4°C until required for analysis. To obtain fractions with different polarities from the crude extract, it was re-dissolved in 250 mL of distilled water and partitioned (3×) with equal volumes of n-hexane, dichloromethane, ethyl acetate, and butanol. The fractions were then concentrated under reduced pressure.

Experimental animals

The study employed healthy adult male Wister rats (180-200g) bred in the experimental animal house of the Institute of Advanced Malaria Research and Training (IAMRAT), University of Ibadan, Ibadan, Nigeria. The animals were housed in cages within the animal facility and provided unrestricted access to both water and standard livestock pellets. Prior to the commencement of the experiment, the animals were examined to ensure they were free from wounds, swellings, and infections.

Preparation of the Extract and Standard Drug for Pharmacological Evaluations

The methanol crude extract of *Uvaria chamae* and the standard, Prednisolone, were dissolved separately in distilled water.

Doses

Experimental doses of 50, 100, 200, and 400 mg/kg body weight of extracts were selected to be given orally. The reference drug, prednisolone, was administered intraperitoneally at a dose of 2 mg/kg. This dose was calculated by converting the therapeutic dose that is used in humans to a rat's dose according to the Table of Paget and Barnes (1964). A 4 % acetic acid solution was prepared by diluting it in normal saline and administered into the rats' colon of rats through a rubber cannula at a dose of 4 mL/kg.

Experimental Design

Thirty-five (35) male Wister albino rats were randomly allocated into 7 equal groups of 5 animals each: Groups 1 and 2 served as the healthy and colitis control groups, respectively, receiving distilled water. Group 3, designated as the reference group, was administered prednisolone at a dose of 2 mg/kg. Groups 4-7 were treated with varying doses (50, 100, 200, and 400 mg/kg) of the methanol extract of *Uvaria chamae* dissolved in distilled water. The extract was orally administered using an orogastric cannula once a day for 2 consecutive days, with the last dose given 2 h before inducing colitis. Treatment continued for 7 consecutive days before harvesting the colon from the experimental rats.

Ethical consideration

The experimental procedures and protocols employed in this study adhered to the Guide to the Care and Use of Animals in Research and Teaching (NIH publications number 85-93, revised in 1985).

Induction of ulcerative colitis

After a 24-hour fasting period with access to water *ad libitum,* rats were lightly anaesthetized using sodium pentobarbitone. A 2 mm diameter rubber cannula was then inserted through the rectum into the colon, reaching a distance of 6 cm (Ghaneya and Gamal, 2010). To induce ulcerative colitis, 1 mL of 4% (v/v) acetic acid was infused into the colons of all the rats (excluding the healthy group that was given distilled water) through the cannula and retained for 3 minutes. Subsequently, the cannula was left in place for a brief period before being gently removed.

Assessment of colonic inflammation and damage

All assessments of damage and excision of tissue samples were conducted by an observer unaware of the treatment groups. Prior to sacrifice, the rats in the various treatment groups were randomized. Following weighing, the rats were euthanized with an overdose of sodium pentobarbitone, and the proximal 10 cm of the colon was removed. A longitudinal incision was made to open the colon, which was then thoroughly rinsed in ice-cold normal saline. The weight of each rat's colon specimen was measured, and the wet weight/length ratio was calculated, representing the ratio of the colon specimen weight to its length (mg/cm). This ratio served as a parameter to evaluate the degree of colon edema, which reflected colitis severity. The colonic damage was further scored based on the criteria outlined by Camuesco *et al.* (2005), with a scoring range of 0-10 reflecting the severity of inflammation and ulceration.

Microscopic (Histopathological) Examination

Histopathological examination of the colon was performed across all groups to assess the healing status. Tissue samples measuring approximately 0.5 cm × 0.5 cm were extracted from the colon, fixed in 10% buffered formalin, and then embedded into paraffin wax blocks as per the methodology outlined by Gautam *et al.* (2013). Sections of 10 µm thickness were prepared for Hematoxylin and Eosin staining (H & E), and slides were examined under a microscope for histopathological changes in a blinded manner. A trained pathologist, unaware of the experimental groups, carried out both microscopic and histological scoring

Evaluation of TNF-α Using Enzyme-Linked Immunosorbent Assay [ELISA]

Each minced distal colon segment was weighed and then placed in separate test tubes containing 10 mM sodium phosphate buffer (pH 7.4; 1:5 wt/vol), following a previously described procedure (Camuesco *et al.*, 2005). The test tubes were placed

in a shaking water bath at 37 °C for 20 min, followed by centrifugation at 9000 g for 30 seconds at 4 °C. The quantification of TNF-α was performed using a rat TNF-α kit (Biolengend®) and the results were expressed as picograms per gram of wet tissue.

Determination of Biochemical Parameters

The colon was divided into four segments for subsequent biochemical determinations. One section was frozen at -80°C for myeloperoxidase (MPO) activity assessment, while two additional samples were weighed and frozen in 1 mL of 50 g/L trichloroacetic acid for the determination of reduced glutathione content (GSH) and superoxide dismutase (SOD). All biochemical measurements were conducted within one week from the time of sample collection and were performed in duplicate. Myeloperoxidase (MPO) activity was assessed following the technique described by Krawisz *et al.* (1984), and the results were expressed as MPO units per gram of wet tissue, where one unit of MPO activity was defined as the degradation of one mmol of hydrogen peroxide per minute at 25 °C. The quantification of reduced glutathione content was conducted according to the method of Beutler *et al.* (1963) with some modifications, and the results were expressed as nanomoles per gram of wet tissue. The level of superoxide dismutase (SOD) activity was determined using the method described by Mistra and Fridovich (1972), with certain modifications.

Nitric Oxide Scavenging Assay of the Crude Extract and Fractions

For the quantification process, the plant extract and fractions were dissolved in distilled water, as described by Panda *et al.* (2009). Sodium Nitroprusside (40 mM) in standard phosphate buffer saline (20 mM, pH 7.4) was introduced to various concentrations (25-800 µg/mL) of the extract and fractions in tubes and were incubated at 29ºC for 3 hours. A control experiment, mirroring the conditions but lacking the test samples, was carried out in the same manner with equivalent amounts of buffer.

After the 3-hour incubation period, equal volumes of supernatant from the samples and freshly prepared Griess reagent were transferred into a 96-micro-well plate. The mixture was then incubated for 10-15 minutes, and the absorbance of the developed colour during the diazotisation of nitrite with sulphanilamide, followed by its subsequent coupling with naphthyl ethylenediamine hydrochloride, was observed at 550nm using a spectrophotometer. The same procedure was applied to gallic acid, which served as a reference standard for comparison with the test agents. A 1:50 dilution of 10 mM of $NaNO_2$ was used to create the calibration curve. The percentage inhibition ability of the plant extracts for the negative control was calculated using the formula:

% inhibition = (Average of the test)/ (Average of control) ×100

Statistical analysis

The data were presented as the mean ± standard error of the mean (SEM). Statistical significance between means was assessed using a one-way analysis of variance (ANOVA) with the Tukey post hoc test. A P-value less than 0.05 was considered statistically significant.

Results and Discussion

Rats treated with acetic acid exhibited symptoms such as prostration, piloerection, and hypomotility. Macroscopic examination of the caecum, colon, and rectum revealed severe colonic mucosal damage characterized by edema, deep ulcerations, and hemorrhage. The animals displayed marked anorexia, with a considerable reduction in average food intake compared to the healthy, vehicle-treated (healthy) group variations (Table 1). Furthermore, the rats treated with acetic acid frequently experienced a significant increase in the weight/length ratio of the colon (indicative of inflammation) and diarrhea. Conversely, treatment with *Uvaria chamae* extract (at doses ranging from 50-400 mg/kg) significantly ($P<0.05$) attenuated the extent and severity of the colonic injury.

Table 1. Effect of UCME on physical parameters; feed intake, water intake, diarrhea level, colon weight/length and damage score in Acetic Acid Experimental Colitis in Rats.

Groups	Feed intake (g)	Water intake (mL)	Diarrhea Score (0-3)	Colon weight/length (mg/cm)	Colon damage score (0-10)
Healthy (distilled water)	89.0.5±6.49	158±18.78	0.00±0.00	66.3±7.54	0.0±0.00
Untreated	21.67±1.82	36.16±3.50	3.00±0.00	198.9±24.7	6.5±0.50
Prednisolone (2 mg/kg)	71.63±7.6#	137±23.51#	1.67±0.44#	80.3±10.32#	2.92±0.11#
50mg/kg UCME	44.90±0.73	87.00±11.82	1.92±0.27#	124.0±8.9	4.86±0.90
100 mg/kg UCME	43.67±3.51	83.83±11.37	1.95±0.23#	151.0±12.3	4.97±0.76
200 mg/kg UCME	57.16±4.95#	111±20.6#	1.86±0.32#	93.9±6.4#	3.21±0.23#
400 mg/kg UCME	66.0±5.6#	125±9.9#	1.12±0.32#	83.1±10.2#	3.06±0.30#

Data are expressed as means ± SEM. #p<0.05 compared to Untreated colitic group; n=5.
Key=UCME: *U. chamae* methanol extract

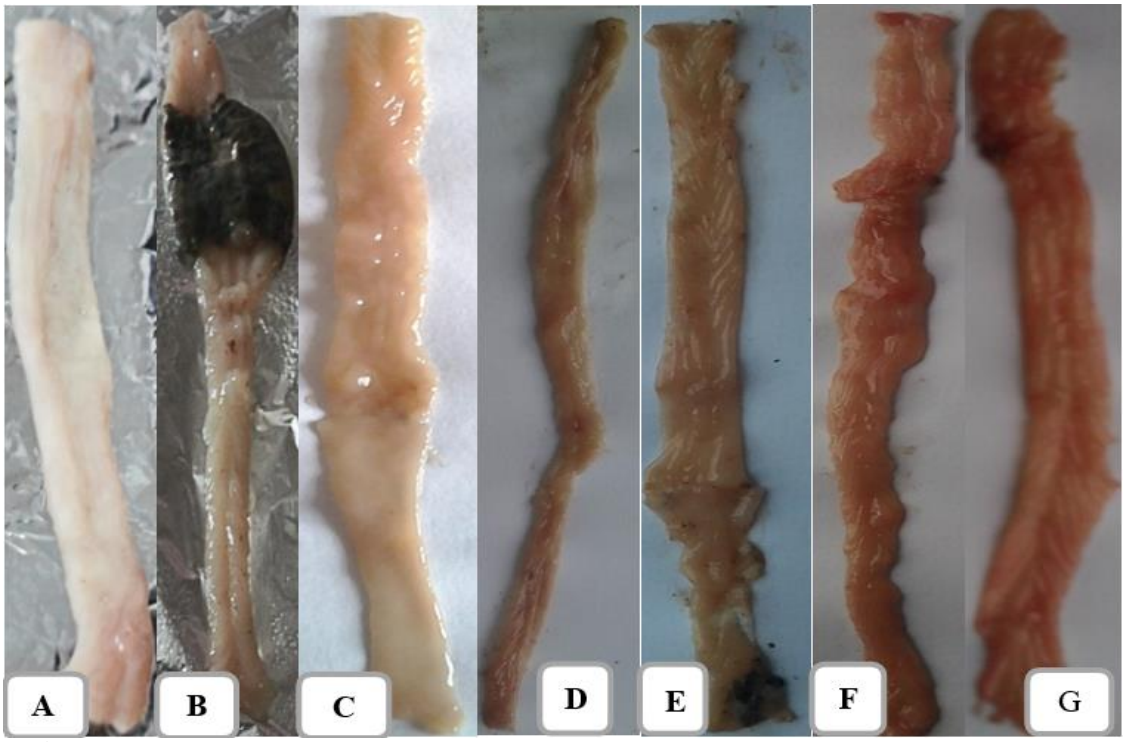

Figure 1: Macroscopic presentation of acetic acid-induced colitis in rats: A: Healthy; B: Untreated colitis C: Prednisolone treated; D: 50 mg/kg UCME; E: 100 mg/kg UCME; F: 200 mg/kg UCME; G: 400 mg/kg UCME. UCME: *U. chamae* methanol extract

This was evidenced by a reduction in the macroscopic damage score ($P<0.05$) (Figure 1), and a decrease in the weight/length ratio of the rat colon, in the presence of diarrhea (Table 1). As shown in Table 2, histopathological examination of the rat's colon cross-sections revealed normal-looking mucosal epithelium with no necrosis or inflammation in the healthy group. In the Acetic Acid-induced group, a diffused active UC was seen along with severe necrosis and inflammation associated with ulceration, hyperemia, cellular infiltrate, and goblet cell hyperplasia (Table 2). Treatment with *U. chamae* extract (100 mg/kg p.o) resulted in slight healing of epithelial cell ulceration with a moderate degree of necrosis and inflammation and fewer goblet cells (Table 2). Colon tissues of animals treated with Prednisolone (2 mg/kg) as a standard revealed normal-looking mucosal epithelium with no necrosis or inflammation in the healthy group.

In the Acetic Acid-induced group, a diffused active UC was seen along with severe necrosis and inflammation associated with ulceration, hyperemia, cellular infiltrate, and goblet cell hyperplasia (Table 2). Treatment with *U. chamae* extract (100 mg/kg p.o) resulted in slight healing of epithelial cell ulceration with a moderate degree of necrosis and inflammation and fewer goblet cells (Table 2).

Colon tissues of animals treated with Prednisolone (2 mg/kg) as a standard drug showed markedly healed and improved intestinal mucosa that can be compared to colon sections from control animals (Table 2). In contrast to non-colitic rats (healthy group) (83.24±11.95 pg/g tissue), the amount of TNF-α, a pro-inflammatory cytokine, was significantly higher in untreated colitic rats (1170.71±19.09 pg/g tissue). The level of TNF-α was significantly reduced after treatment with graded dosages of *U. chamae* extract, with the highest dose producing the maximum activity (200.86±4.14 pg/g tissue).

Table 2. Effect of *U. chamae* on microscopic scoring of histopathological sections of colonic tissue of rats with acetic acid-induced ulcerative colitis, n=5

Groups	Ulceration	Hyperaemia	Necrosis	Cellular infiltrate	Goblet cell hyperplasia
Healthy (Distilled water)	0	0	0	0	0
Untreated colitis	+++	+++	++++	++++	++
Prednisolone (2 mg/kg)	0	+	0	0	+
50 mg/kg UCME	++	+	0	+	+
100 mg/kg UCME	+	+	+	++	+
200 mg/kg UCME	+	++	0	+	+
400 mg/kg UCME	0	++	0	0	+

0: Normal; +: Mild; ++: Moderate; +++: Severe; ++++: Very severe. Key=UCME: *U. chamae* methanol extract

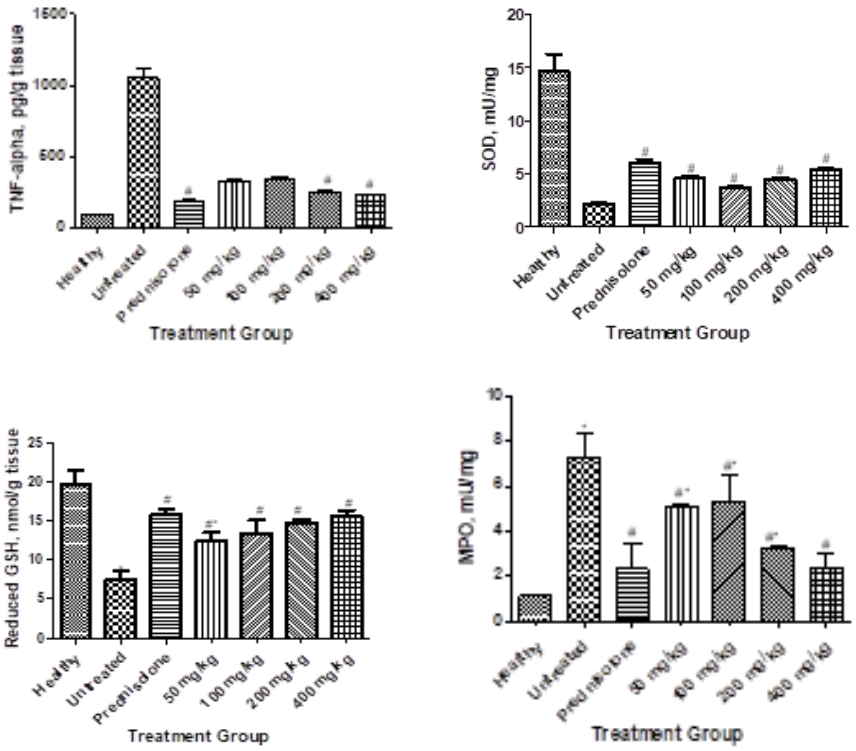

Figure 2. (a) Effects of graded doses of *U. chamae* stem bark methanol extract on the Tumor necrotic factor alpha (TNF-α) in acetic acid-induced rat colitis. Data are expressed as means±SEM. #P≤0.05 vs. untreated colitic (negative control) group (b) Effects of graded doses of methanol extract of *U. chamae* stem bark on the colonic superoxide dismutase (SOD) in acetic acid-induced rat colitis. Data are expressed as means±SEM. #P≤0.05 vs. untreated colitic (negative control) group (c) Effects of graded doses of methanol extract of *U. chamae* stem bark on the colonic Glutathione (GSH), in acetic acid-induced rat colitis. Data are expressed as means±SEM. #P≤0.05 vs. untreated colitic (negative control) group. (d) Effects of graded doses of U. chamae stem bark methanol extract on the colonic Myeloperoxidase (MPO) in acetic acid-induced rat colitis. Data are expressed as means±SEM. #P≤0.05 vs. untreated colitic (negative control) group

Activities of the antioxidant enzymes SOD and GSH were significantly (P <0.01 and P <0.05, respectively) inhibited in the colons of acetic acid-administered rats compared to control animals. Treatment with doses (50, 100, 200, and 400 mg/kg) of *U. chamae* showed a marked increase in SOD and GSH content (P<0.05) compared to the untreated acetic acid group. Also, significant improvement in the levels of MPO was observed (P< 0.05) compared to the untreated group (Figure 2). As for the standard drug, Prednisolone, its activity against UC was better but there was no significant difference with the extract of *U. chamae* concerning all the parameters (P=0.05).

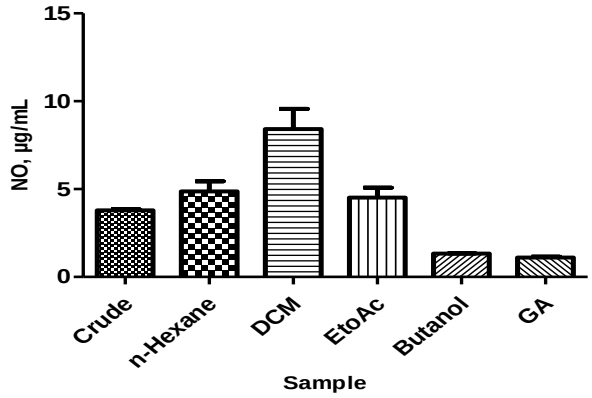

Figure 3: Nitric oxide inhibitory activity of the *U. chamae* crude extract and partitioned fractions in comparison with the standard, Gallic acid. Each value is the average of three replicates ± SEM. Key=DCM- dichloromethane; EtoAc- ethylacetate; GA- Gallic acid

The crude methanol extract (3.8±0.11 µg/mL) and fractions of *U. chamae* including n-hexane (4.87±0.17 µg/mL), dichloromethane (8.42±0.51 µg/mL), ethylacetate (5.47±0.19 µg/mL, and butanol (1.31±0.09 µg/mL) demonstrated a significant decrease in the nitric oxide radicals due to their scavenging ability when compared with the standard (Gallic acid) with IC_{50} value of 1.1±0.1 µg/mL (Figure 3).

In this study, it was shown for the first time that administering stem bark extract from the *Uvaria chamae* plant can significantly reduce the severity and extent of acute colonic injury caused by acetic acid. Notably, the administration of the extract resulted in a lower incidence of diarrhea and an increase in feed and water intake. Conversely, the rectal administration of acetic acid led to a significant increase in animal colon weights, indicating severe tissue ulceration, necrosis, goblet cell hyperplasia, and inflammatory infiltration. This aligns with previous studies using the same animal model (Harputluoglu *et al*., 2006; El-Abhar *et al*., 2008). In contrast, treatment with *U. chamae* extract resulted in a reduction in animal colon weight (Tables 1 and 2).

IBD is characterized by a defect in the colonic mucosal barrier functioning, as noted by Liu *et al*. (2021). The current study found that acetic acid caused a significant alteration in the protective intestinal mucus, which is consistent with Popov *et al*. (2006) and Abiodun *et al*. (2017). Chemically injured epithelium heals faster with the aid of the mucus layer (Al-Rejaie *et al*., 2012). The extract and prednisolone were found to increase the amount of mucus in the colon mucosa significantly. This increase is primarily due to the secretory by-products of intestinal goblet cells, as the mucus layer plays a

significant role in innate host defence in the digestive tract (Kim and Ho, 2010). Recent data suggests that complex interactions, such as impaired mucosal barrier function resulting from abnormal mucin synthesis and/or processing, contribute to the pathophysiology of IBD (Kim and Ho, 2010). Decreased goblet cell numbers and size were observed in ulcerative colitis (UC). An increased amount of intestinal mucus, as observed in our study, could be helpful in the treatment or prevention of intestinal disorders (Kim and Ho, 2010).

Studies have indicated that individuals with IBD and TNBS-induced colitis show an increase in cytokine levels, such as TNF-α, released from immune and endothelial cells (Zhang *et al*., 2018; Wu *et al*., 2021). There was a significant elevation of TNF-α, a pro-inflammatory cytokine, in the colon of untreated colitic rats. However, administering the methanol extract of *U. chamae* at the recommended doses helped reduce colonic TNF-α levels, mitigating the exacerbation of the inflammatory process. In chronic inflammation of the large intestine, plasma cells and lymphocytes increase, while neutrophils move actively and release enzymes like myeloperoxidase (MPO) (Masoodi *et al*., 2011). MPO, an enzyme present in the main granules of polymorphonuclear neutrophils, acts as an inflammation indicator in the digestive tract (Masoodi *et al*., 2011). Colitis caused by substances such as TNBS and DSS is widely recognized to result in elevated MPO levels (De-Faria *et al*., 2012). Conversely, *U. chamae* extract resulted in decreased MPO activity in the inflamed colon, indicating an inhibitory effect on granulocyte infiltration. Rats that were exposed to acetic acid-induced acute inflammation showed lower levels of superoxide dismutase (SOD) and reduced glutathione (GSH). The study's results indicated that the administration of *U. chamae* extract (at doses of 50-400 mg/kg p.o) and prednisolone restored the depleted levels of glutathione (GSH). The flavonoids with antioxidant properties present in *U. chamae* may be credited with this recovery, as they have been found to have protective effects in preventing and treating inflammatory processes within the intestines that are caused by various chemicals that induce experimental colitis. These effects include scavenging free radicals, interacting with oxidative cascade, inhibiting oxidative enzymes, and chelating oxidative metal ions (Zhang *et al*., 2011).

The relationship between nitric oxide (NO), reactive oxygen species (ROS), and various pathological conditions, including inflammation and cancer, has been well-established (Lee *et al*., 2019). NO is a common free-radical molecule found in many tissues and organs and is believed to act as a neurotransmitter or neuromodulator in the central nervous system (Abu *et al*., 2021). Our research suggests that the extract from *U. chamae* may have protective or therapeutic effects on the gastric mucosa against different types of necrotic agents. Therefore, the butanol fraction may contain molecules that have anti-colitic properties.

Conclusion

Our research findings indicate that administering *Uvaria chamae* stem bark extract orally to rats with colitis induced by acetic acid may help reduce the severity of damage to the mucosal lining of the colon, alleviate the increase in myeloperoxidase (MPO) activity, and restore diminished antioxidant enzymes such as superoxide dismutase (SOD) and glutathione (GSH). *U. chamae* extract demonstrated a protective effect against lipid peroxidation in the colon triggered by acetic acid, especially at higher doses (200 & 400 mg/kg orally). The stem bark of *U. chamae* shows potential as a therapeutic approach to managing inflammatory conditions. However, additional research is necessary to identify the specific molecule(s) responsible for the observed bioactivity.

Declaration of interest

The authors have no relevant financial or non-financial interests to disclose.

Acknowledgement

The authors acknowledge Mrs. Braimah's technical assistance during the study.

References

1. Abiodun, O.O., Oshinloye, A.O. (2017). *Carpolobia lutea* G. Don (Polygalaceae) Inhibits Inflammation and Oxidative Stress in an Acetic Acid Induced Model of Rat Colitis. Drug Research, 67: 20-24.
2. Abu, T., Ogbole, O.O. and Ajaiyeoba, E.O. (2021). Radical Scavenging Activity, Brine Shrimp Lethality Assay and HPLC Analysis of Methanol Extracts of *Secamone afzelii* (Roem. & Schult.) K. Schum and Ceibapentandra (Linn.) Gaertn. Nigerian Journal of Pharmaceutical Research, 17(2):233-244.
3. Abu, T., Rex-Ogbuku, E.M. and Idibiye, K. (2018). A review: secondary metabolites of *Uvaria chamae* p. Beauv. (Annonaceae) and their biological activities. International Journal of Agric, Environment and Food Sciences, 2(4):177-185.
4. Akinyinka, O.O., Adepoju, A.A., Ashubu, O.F., Ogunbosi, B.O., Olatunji, R.B., Akere, A., Orimadegun, A.E. and Oluwasola, A.O. (2019). Ulcerative colitis in Nigerian children: A report of two cases and review of the literature. Nigerian Journal of Paediatrician, 46(4):200-205.
5. Al-Rejaie, S.S., Abuohashish, H.M., Ahmed, M.M., Aleisa, A.M. and Alkhamees, O. (2012). Possible biochemical effects following inhibition of ethanol-induced gastric mucosa damage by *Gymnema sylvestre* in male Wistar albino rats. Pharmaceutical Biology, 50(12):1542-1550.
6. Ayensu, E.S. (1978). Medicinal Plants of West Africa. Reference Publications, Inc., Algonac, Michigan, 41.
7. Beutler, E., Duron, O. and Kelly, M.B. (1963). Improved method for determination of blood glutathione. The Journal of Laboratory and Clinical Medicine, 61: 882-887.
8. Camuesco, D., Peran, L., Comalada, M., Nieto, A., Di Stasi, L.C., Rodriguez-Cabezas, M.E., Concha, A., Zarzuelo, A. and Galvez, J. (2005). Preventative effects of lactulose in the trinitrobenzene sulphonic acid model of rat colitis. Inflammatory Bowel Diseases, 11, 265-271.
9. Coelho, I.P., Santos, L.B.B.D., Kato Junior, W.H., Corsino, J., Cordeiro, K.W., Boeing, T., Coelho, J.M., Garcez, F.R., Garcez, W.S., de Andrade, S.F. and Figueiredo, P.O. (2020). Chemical profile and gastroprotective effect of *Jatropha elliptica* (Pohl) Oken roots. Fitoterapia, 146:104707.
10. Ghaneya, S.H. and Gamal, A.S. (2010). Design, synthesis and anti-ulcerogenic effect of some of furo-salicylic acid derivatives on acetic acid-induced ulcerative colitis. European Medicinal Chemistry, 45, 4104-4112.
11. De-Faria, F.M., Luiz-Ferreira, A., Socca, E.A., deAlmeida, A.C., Dunder, R.J., Manzo, L.P.,

daSilva, M. A., Vilegas, W., Rozza, A. L., Pellizzon, C.H., DosSantos, L.C. and Souza Brito, A.R. (2012). Effects of *Rhizophora mangle* on experimental colitis induced by TNBS in rats. Evidence-Based Complementary and Alternative Medicine, 753971.

12. El-Abhar, H.S., Hammad, L.N. and Gawad, H.S. (2008). Modulating effect of ginger extract on rats with ulcerative colitis. Journal of Ethnopharmacology, 118(3):367-372.
13. Fukuda, T., Naganuma, M., Kanai, T. (2019). Current new challenges in the management of ulcerative colitis. Intestinal Research, 17(1):36-44.
14. Gautam, M.K., Goel, S., Ghatule, R.R., Singh, A., Joshi, V.K. and Goel, R.K. (2013). *Azadirachta indica* attenuates colonic mucosal damage in experimental colitis induced by TNBS acid. Indian Journal of Pharmaceutical Science, 75(5): 602-606.
15. Harputluoglu, M.M., Demirel, U., Yucel, N., Karadag, N., Temel, I., Firat, S., Ara, C., Aladag, M., Karincaoglu, M. and Hilmioglu, F. (2006). The effects of *Gingko biloba* extract on acetic acid-induced colitis in rats. Turkish Journal of Gastroenterology, 17(3):177-182.
16. Keshteli, A.H., Madsen, K.L. and Dieleman, L.A. (2019). Diet in the Pathogenesis and Management of Ulcerative Colitis; A Review of Randomized Controlled Dietary Interventions. Nutrients, 30; 11 (7):1498.
17. Kim, Y.S. and Ho, S.B. (2010). Intestinal goblet cells and mucins in health and disease: recent insights and progress. Current Gastroenterology Reports, 12, 319–330.
18. Kobayashi, T., Siegmund, B., Le Berre, C., Wei, S.C., Ferrante, M., Shen, B., Bernstein, C.N., Danese, S., Peyrin-Biroulet, L. and Hibi, T. (2020). Ulcerative colitis. Nature Review Disease Primers, 6(1):74.
19. Krawisz, J.E., Sharon, P. and Stenson, W.F. (1984). Quantitative assay for acute intestinal inflammation based on myeloperoxidase activity: assessment of inflammation in rat and hamster models. Gastroenterology, 87:1344-1350.
20. Kuenzig, M.E., Fung, S.G., Marderfeld, L., Mak, J.W.Y., Kaplan, G.G., Ng, S.C., Wilson, D.C., *et al.* (2022). Insight Scope Pediatric IBD Epidemiology Group; Benchimol EI. Twenty-first Century Trends in the Global Epidemiology of Pediatric-Onset Inflammatory Bowel Disease: Systematic Review. Gastroenterology, 162(4):1147-1159.
21. Lee, A.Y., Choi, J.W., Yokozawa, T. and Cho, E.J. (2019). Preventive effect of oligonol on nitric oxide and reactive oxygen species production through regulation of nuclear factor kappa B signalling pathway in RAW 264.7 macrophage cells against sodium nitroprusside. RSC Advances, 9(7):3987-3993.
22. Lin, Z., Wu, H., Fu, Y. and Dai, S. (2019). Application of Herbaceous Medications for Inflammatory Bowel Disease as a Complementary and Alternative Therapy. Inflammatory Bowel Diseases, 25(12):1886-1895.
23. Liu, N., Feng, G., Zhang, X., Hu, Q., Sun, S., Sun, J., Sun, Y., Wang, R., Zhang, Y., Wang, P. and Li, Y. (2021). The Functional Role of Lactoferrin in Intestine Mucosal Immune System and Inflammatory Bowel Disease. Frontier in Nutrition, 25; 8: 759507.
24. Masoodi, I., Tijjani, B.M., Wani, H., Hassan, N.S., Khan, A.B. and Hussain, S. (2011). Biomarkers in the management of ulcerative colitis: a brief review. German Medical Science, 9, 1-7.
25. Mistra, H.P. and Fridovich, I. (1972). The role of superoxidase anion in the autoxidation of Epinephrine and a simple Assay for Superoxide Dismutase. The Journal of Biological Chemistry, 247(10):3170-3175.
26. Okwu, D.E. and Iroabuchi, F. (2009). Phytochemical composition and biological activities of *Uvaria chamae* and *Clerodendrum splendens*. European Journal of Chemistry, 6:553-560.
27. Panda, B.N., Raj, A.B., Shrivastava, N.R. and Prathani, A.R. (2009). "The evaluation of nitric oxide scavenging activity of *Acalypha indica* Linn Root". Asian Journal Research Chemistry, 2(2):148-150.
28. Pavlick, K.P., Laroux, F.S., Fuseler, J., Wolf, R.E., Gray, L., Hoffman, J. and Grisham, M.B. (2002). Role of reactive metabolites of oxygen and nitrogen in inflammatory bowel disease. Free Radical Biology and Medicine, 33(3):311-322.
29. Popov, S.V., Markov, P.A., Nikitina, I.R., Petrishev, S., Smirnov, V. and Ovodov, Y.S. (2006). Preventive effect of a pectic polysaccharide of the common cranberry *Vaccinium oxycoccos* L. on acetic acid-induced colitis in mice. World Journal of Gastroenterology, 12(41):6646-6651.
30. Reiff, C. and Kelly, D. (2010). Inflammatory bowel disease, gut bacteria and probiotic therapy. International Journal of Medical Microbiology, 300(1):25-33.
31. Sood, A., Midha, V., Sood, N., Bhatia, A.S. and Avasthi, G. (2003). Incidence and prevalence of ulcerative colitis in Punjab. North Indian Gut, 52(11):1587-1590.
32. Taylor, S. and Lobo, A.J. (2016). Diagnosis and treatment of inflammatory bowel disease. Practitioner, 260(1795):19-23.
33. Wu, F., Shao, Q., Cheng, Z., Xiong, X., Fang, K., Zhao, Y., Dong, R., Xu, L., Lu, F. And Chen, G. (2021). Traditional herbal formula Wu-Mei-Wan alleviates TNBS-induced colitis in mice by inhibiting necroptosis through increasing RIPK3 O-GlcNAcylation. Chinese Medicine, 16(1):78.
34. Yakubu, M.T. and Fayemo, H.T. (2021).Anti-hyperprolactinemic activities of aqueous extract of *Uvaria chamae* (P. Beauv) roots and associated biochemical changes in chlorpromazine-induced hyperprolactinemic female Wistar rats. Journal of Ethnopharmacology, 271, 113863.
35. Zhang, A., Fang, Y., Wang, H., Li, H. and Zhang, Z. (2011). Free-radical scavenging properties and reducing the power of grape cane extracts from 11 selected grape cultivars widely grown in China. Molecules, 16, 10104-10122.
36. Zhang, C., Shu, W., Zhou, G., Lin, J., Chu, F., Wu, H. and Liu, Z. (2018). Anti-TNF-α Therapy Suppresses Proinflammatory Activities of Mucosal Neutrophils in Inflammatory Bowel Disease. Mediators Inflammation, 3021863.